



## Single-Stage Versus Two-Stage Urethroplasty for Hypospadias

Vincent Anggriant<sup>1</sup>, Dahlan Sianturi<sup>2</sup>, Rajin S Saragih<sup>3</sup>, Parbarita Sibarani<sup>4</sup>, Johnliberti Purba<sup>5</sup>, S L Margareth Gultom<sup>6</sup>

General Practitioner, Regional Public Hospital dr. Djasamen Saragih, Faculty of Medicine, The Methodist University of Indonesia, North Sumatera, Indonesia<sup>1</sup>

Pediatric Surgeon, Regional Public Hospital dr. Djasamen Saragih, Pematang Siantar, North Sumatera, Indonesia<sup>2</sup>

Surgeon, Regional Public Hospital dr. Djasamen Saragih, Pematang Siantar, North Sumatera, Indonesia<sup>3,4</sup>

Pediatrician, Regional Public Hospital dr. Djasamen Saragih, Pematang Siantar, North Sumatera, Indonesia<sup>5,6</sup>

Email: vincent.anggriant@gmail.com

---

### KEYWORDS

Hypospadias, Urethroplasty, Single-Stage Urethroplasty, Two-Stage Urethroplasty.

---

### ABSTRACT

This study aims to evaluate the effectiveness of single-stage and two-stage urethroplasty procedures in hypospadias repair. Researchers conducted a systematic review of relevant literature using medical databases and manual searches of relevant articles. We assessed the outcomes of clinical studies related to single-stage and two-stage urethroplasty techniques, as well as identifying the advantages and disadvantages of each. Our review findings indicate that single-stage urethroplasty offers advantages in terms of shorter hospital stays and increased comfort for both patients and medical staff. However, two-stage urethroplasty has advantages in more aggressive chordee correction and lower recurrence rates. Nevertheless, there is no one-size-fits-all approach to hypospadias repair, as the choice of urethroplasty technique often depends on the preferences and specific expertise of individual surgeons. This research highlights the importance of selecting the appropriate urethroplasty technique based on patient characteristics and surgeon expertise. Future research needs to expand our knowledge of factors influencing the success of urethroplasty procedures to guide better clinical decision-making in hypospadias management.

---

DOI: 10.58860/ijsh.v3i3.181

**Corresponding Author:** Vincent Anggriant \*

**Email:** vincent.anggriant@gmail.com

## INTRODUCTION

Hypospadias is a congenital anatomical abnormality affecting the external genitalia in males. The condition is distinguished by atypical development of the urethral fold and the ventral foreskin of the penis, resulting in anomalous placement of the urethral opening (Kraft et al., 2010; Snodgrass, 2011; Stein, 2012; van der Horst & de Wall, 2017). Hypospadias is widely recognized as the number one congenital anomaly affecting the penis with a very heterogeneous number (Bergman et al., 2015; Springer et al., 2016). A study in South America reported a prevalence of 11.3 in 10,000 newborns (Fernández et al., 2017). In the United States (US) reported a prevalence of up to 6.8 in 1000 births (Chen et al., 2018), and in Sweden it reached up to 8 per 1,000 newborns (Nordenvall et al., 2014). A systematic review of boys with hypospadias reported that the findings regarding psychosocial and psychosexual adjustment were inconclusive in studies that they had included. However, they indicated that boys with hypospadias experience adverse evaluation of their genitals and sexual inhibitions (Schönbucher et al., 2008).

Individuals diagnosed with hypospadias should undergo surgical evaluation within the first weeks of birth to address both physical and psychological challenges associated with the condition. Early surgical intervention, typically recommended between 6 and 18 months of age, aims to minimize potential psychological distress and behavioral complications that may arise if the procedure is delayed until later developmental stages (Keays & Dave, 2017; Manzoni et al., 2004).

Over the years, there have been advancements in surgical treatments for hypospadias. However, the fundamental principles of any surgical procedure for this condition have remained consistent. The procedural stages of hypospadias surgery encompass penile degloving, orthoplasty for correcting ventral curvature, urethroplasty for urethral reconstruction, vascularized covering for urethroplasty, and glansplasty for glans reconstruction (Keays & Dave, 2017; Steven et al., 2013).

There have been extended indications for single-stage repairs to manage the discomfort and potential hazards associated with a subsequent treatment, as well as the customary six-month waiting period between stages (Babu & Chandrasekharam, 2021; Dason et al., 2014; Hoy et al., 2019). However, the two-stage repair is currently experiencing a resurgence in popularity due to its ability to simultaneously decrease morbidity and enhance cosmesis in the treatment of the most severe types of hypospadias (Haxhirexha KN et al., 2008).

This research offers a significant contribution to the existing literature on hypospadias by providing a thorough examination of surgical interventions and their impact on psychological outcomes in affected individuals. While previous studies have addressed the physical aspects of hypospadias treatment, this research uniquely focuses on the psychological ramifications, particularly in the context of different surgical approaches. By evaluating both single-stage and two-stage repair procedures, the study not only enhances our understanding of the efficacy and safety of these interventions but also sheds light on their implications for the psychological well-being of patients. This holistic approach not only advances the methodology of hypospadias research by integrating psychological assessment but also offers valuable insights for clinicians and healthcare providers, facilitating more informed decision-making and improved patient care. Moreover, by acknowledging the resurgence of interest in two-stage repairs, the research underscores the importance of considering both medical and cosmetic outcomes in the management of hypospadias, thereby enriching the practical implications of the findings for clinical practice.

## **METHOD**

This literature review explores advancements in surgical treatments for hypospadias, focusing on urethroplasty techniques. Single- and two-stage urethroplasty procedures are discussed, each offering distinct advantages. While single-stage procedures are favored for their convenience and shorter hospital stays, recent technical innovations in two-stage procedures provide a more assertive correction of chordee, leading to decreased chordee relapse rates. Hypospadias, a congenital anomaly affecting male external genitalia, has varying prevalence rates globally. Surgical intervention within the first 18 months of life is recommended to mitigate psychological distress. Surgical procedures for hypospadias have remained consistent, involving penile degloving, orthoplasty, urethroplasty, vascularized covering, and glansplasty. The choice between single- and two-stage urethroplasty depends on individual patient conditions and surgeon preference, with conflicting evidence regarding superiority, highlighting the absence of a universal approach.

## **RESULT AND DISCUSSION**

### **Hypospadias**

Hypospadias is a common congenital anomaly in the urogenital system in male infants. Hypospadias is a congenital condition characterized by the displacement of the urethral opening towards the ventral side of the penis. The various phenotypes of hypospadias are classified based on the specific location of the urethral opening. Anterior hypospadias refers to cases where the urethral opening is situated at the glans or corona of the penis. Middle hypospadias occurs when the urethral opening is found on the shaft of the penis. Lastly, posterior hypospadias is characterized by the termination of the urethra in the penoscrotal region, scrotum, or perineum (Stein, 2012; van der Horst & de Wall, 2017; Van Rooij et al., 2013; Xu et al., 2014).

Hypospadias is thought to have a complex origin, where several genes interact with environmental factors. Numerous studies have conducted investigations on the environmental risk factors associated with the occurrence of hypospadias. Although most cases are idiopathic, there is an increased risk of having isolated hypospadias with having a family member affected by the condition. The heritability of hypospadias is estimated to range from 57% to 77% and occurs equally through both maternal and paternal lines (Bouty et al., 2015). Additional factors that contribute to the aforementioned conditions are infants with small gestational age, births involving multiple gestations, premature births, and parental factors such as families with genital anomalies, mothers aged over 35 years, mothers with a history of alcohol or drugs consumption, and mothers who have experienced infections during pregnancy (Chen et al., 2018; Van Rooij et al., 2013; Xu et al., 2014). Families who lived in >5% area covered with crops are also reported to have a possible correlation with hypospadias, although this needs further investigation (Winston et al., 2014).

Kaufmann is widely recognized as the first person who initially categorized hypospadias into three distinct grades: grade I (glanular hypospadias) which refers to cases where the urethral opening is situated within the glans region, grade II (penile hypospadias) which involves the opening being located within the body of the penis up to the penoscrotal junction, and grade III (perineal hypospadias) which is characterized by the opening being positioned proximal to the penoscrotal junction and accompanied by a bifid scrotum. This grading became more popular during the twentieth century, particularly following a publication by Smith in 1938. At present, primary hypospadias is categorized into four distinct grades: glanular (grade I), distal (grade II), proximal (grade III), and perineal (grade IV) (Hadidi, 2022).

Hypospadias could also be classified into four distinct categories: forme fruste, standard hypospadias, severe hypospadias, and hypospadias variations. Forme fruste or incomplete/partial manifestation of hypospadias is distinguished by asymmetrical foreskin and clinically inconsequential meatal irregularities. Standard hypospadias refers to a condition characterized by a typical penile length, a dorsal hooded foreskin that is not fused to the scrotum, a glans size > 13 mm at its widest point, the absence of curvature or the presence of mild to moderate penile curvature, and the absence of penoscrotal transposition. Severe hypospadias is characterized by the presence of an ectopic urethral meatus (typically located in the scrotum or perineum), small glans size (maximum diameter <14 mm), severe curvature (commonly associated with a ventral penile skin tethering or known as a short urethral plate), and fusion of the foreskin to the scrotum, resulting in penoscrotal transposition (Baskin, 2017).

A comprehensive evaluation encompassing a detailed medical history and a meticulous physical examination is required, with particular attention given to the familial occurrence of hypospadias. Currently, the identification of hypospadias typically occurs shortly following the infant's delivery, although a study reported that ultrasound examination during pregnancy could have a high positive predictive value for a penile anomaly (Epelboym et al., 2017). Prominent characteristics during physical examination include encompassing a glandular groove and a dorsal

hood of the foreskin; nonetheless, it is noteworthy that the prepuce is typically incompletely developed on the ventral side not nearly all instances. Furthermore, it is worth noting that the urethral meatus often exhibits an atypical anatomical position. The presence of a fully intact foreskin in an infant may result in the subsequent identification of hypospadias following the circumcision procedure. Certain patients may exhibit a concomitant penile curvature that becomes apparent during the erect state (Keays & Dave, 2017).

Surgical intervention remains elective for hypospadias. The decision is based on family preference and when necessary, with proper physician education. The optimal period for hypospadias surgery often falls within the range of 6 to 18 months, as recommended by the American Academy of Pediatrics and in accordance with standard surgical protocols (Springer et al., 2017).

The fundamental objective of hypospadias treatment is to attain optimal cosmetic and functional outcomes. Regardless of whether it is performed through a single surgery or multiple approaches, the process involves constructing a straight penis with a consistently sized neourethra, terminating in a naturally formed narrow opening at the apex of a restructured glans (Manzoni et al., 2004; Subramaniam et al., 2011).

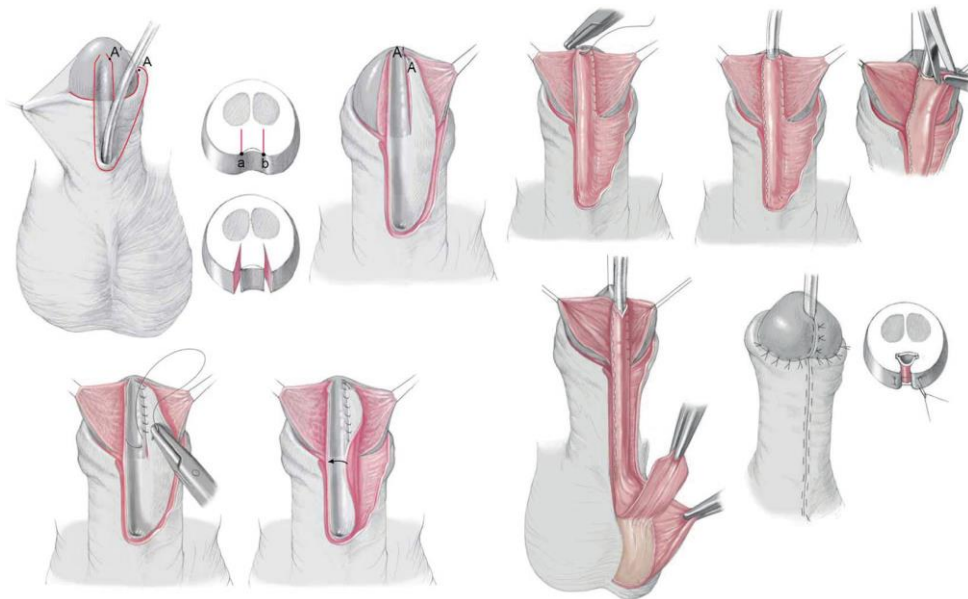
Typically, the repairs conducted throughout the early to mid-twentieth century were performed in a two-stage approach. Edmunds proposed a two-step surgical approach involving the initial release of chordee and subsequent transfer of preputial skin to the ventral region, which would eventually undergo tubularization. During the latter half of the twentieth century, specifically the late 1950s and 1960s, there was an arising enthusiasm for the implementation of one-stage hypospadias repair. In previous eras, surgical procedures involving a single stage utilized split-thickness-free grafts sourced from the thigh or arm, which were associated with various problems, notably significant contracture (Hadidi, 2022). Currently, the tubularized incised plate (TIP) repair is one of the most frequent techniques that is used by surgeons for distal hypospadias (Khan et al., 2014; Steven et al., 2013).

Several complications could be found after hypospadias repair. Among younger boys, meatal stenosis, dehiscence, and urethral strictures were next most frequent. In the older age groups, an increasing frequency of cosmesis, meatal shape/location, and genital skin changes were described (Agrawal & Misra, 2013; Appeadu-Mensah et al., 2015; Leunbach et al., 2020; Ru et al., 2021). There is also a risk of the forming of a urethra-cutaneous fistula (Bush et al., 2015; Duarsa et al., 2020; Sheng et al., 2018).

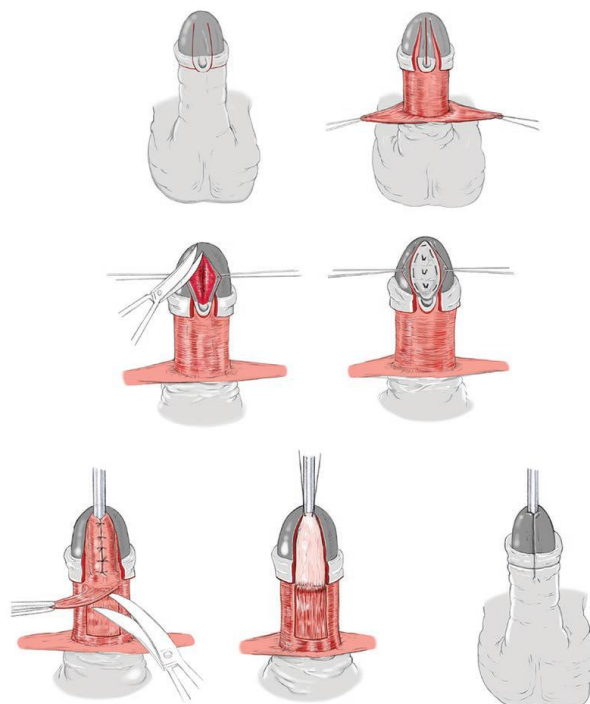
### **Single Stage Urethroplasty**

One-stage procedures are undeniably appealing and highly sought after. Shorter hospital stays and increased convenience for both patients and surgeons are commonly observed with their use in the short term. Most distal cases of hypospadias with mild or no chordee can typically be successfully treated. In the case of glanular and distal hypospadias, the prevailing approach involves the implementation of a one-step surgical intervention. The prevailing strategies utilized for the treatment of glanular hypospadias are double Y glanulomeatoplasty (DYG), advancement, and meatal advancement and glanuloplasty technique (MAGPI). Popular treatments for the management of distal hypospadias include the slit-like adjusted Mathieu (SLAM), Thiersch, and TIP procedures. The lateral-based onlay flap (LABO), tubularized incised plate (TIP), and only island flaps are often employed procedures for the management of proximal hypospadias in the absence of significant chordee. Various surgical techniques are available for the correction of proximal hypospadias accompanied by severe chordee in a single procedure. These techniques include the bilateral-based flap (BILAB), Koyanagi, and Yoke (Aslam et al., 2013; Chandrasekharam, 2013; Cui et al., 2020; Emir et al., 2000; Gite et al., n.d.; Goel et al., 2021; González et al., 2018; Hadidi, 2009, 2022;

Hayashi et al., 2007; Kajbafzadeh et al., 2007; Schwentner et al., 2006; Singal et al., 2016; Tiryaki, 2010).



**Figure 1: The lateral-based onlay technique: The principle is to use the lateral preputial skin as a lateral meatal-based flap (Hadidi, 2022)**



**Figure 2. Dorsal inlay TIP (Hadidi, 2022)**

The TIP repair starts with the degloving of the penis following a circumferential subcoronal incision made approximately ~2 mm proximal to the urethral native meatus. A U-shaped incision is performed along the lateral boundaries of the urethral plate. Subsequently, the glans wings are formed. A relaxing incision is performed along the central axis of the urethral plate in order to facilitate the tension-free tubularization of the urethra. The process of tubularization is subsequently executed using a 6/0 running suture. The technique involves the transplantation of a buttonholed

dartos flap from the dorsal aspect of the penis to the ventral aspect, hence providing coverage for the tubularized neo-urethra. The technique of glans wings approximation initiates the glanuloplasty procedure at the corona. The method is completed by suturing the skin borders and the meatus (Subramaniam et al., 2011).

The TIP repair procedure is employed for proximal hypospadias instances where there is no significant penile curvature and the urethra is pliable and flexible, despite the seeming contradiction. The aforementioned technique is commonly used for treating hypospadias located at the distal and mid-shaft regions. Moreover, it is progressively being employed for proximal hypospadias and revision surgeries. Nevertheless, in the context of proximal hypospadias, there have been documented instances of a complication rate of 33%, including a 21% occurrence of fistula and permanent chordee in certain individuals. According to Snodgrass, it is advocated to prioritize the preservation of the urethral plate to the greatest extent feasible, resorting to its sacrifice only in instances of severe penile curvature. Nevertheless, it is important to note that achieving favorable outcomes may not be feasible for every urethral plate (Aslam et al., 2013; Bhat et al., 2014).

Duckett can be credited with the popularization of the preputial island flap technique. Following the process of degloving the penis and chordee correction, the inner prepuce is elevated as a pedicle flap and subsequently relocated to the ventral side to provide coverage for the urethral plate as an onlay graft. The urethral plate is responsible for forming the upper surface of the neo-urethra. The utilization of an onlay technique serves to circumvent the occurrence of circular anastomosis, hence mitigating the risk of stricture formation. It is important to proceed with caution in utilizing an optimal amount of preputial skin and to customize it accordingly to mitigate the risk of a lax urethra which might lead to the development of a urethral diverticulum. The Asopa variation of the operation involves utilizing the inner prepuce as a pedicle flap while maintaining the attachment of the neourethra to the underlying surface of the foreskin. Consequently, a shared blood supply exists between the skin and the neo-urethra (Chandrasekharam, 2013; González et al., 2018; Subramaniam et al., 2011).

Gaining a comprehensive understanding of the risk factors linked to the complications arising from single-stage hypospadias surgery in patients might contribute to improved results. A study identified several significant risk factors for postsurgery problems such as glans width, urethral plate width and shape, and a history of previous surgery. From these risk factors, it was determined that the width of the glans is an independent and statistically significant risk factor for complications in single-stage urethroplasty (Goel et al., 2021).

The Koyanagi treatment involves the extraction of a lengthy and broad strip from the skin of the penile shaft, which is done in conjunction with the preputial hood. Subsequently, the aforementioned process is conveyed in a ventral direction and undergoes tubularization, hence enabling a correction to be achieved in a single stage. Subsequent modifications have been implemented in an endeavour to enhance the circulation of blood. The proponents assert that this constitutes a dual-phase process that is effectively executed in a single step (Subramaniam et al., 2011). The reported incidence of complications associated with the Koyanagi operation varies between 20% and 50%. In a recent paper by Jayanthi, the author noted that a considerable proportion of male patients undergoing the modified Koyanagi surgery for proximal hypospadias may require subsequent surgical intervention (Emir et al., 2000). Complication has been reduced by modifying the Koyanagi repair technique through the preservation of a large vascular pedicle for the distal skin flaps and the utilization of the distal urethral plate as the foundation for the distal neourethra. The utilization of this technology presents a viable substitute for a two-stage methodology in addressing the treatment of proximal hypospadias (Hayashi et al., 2007).

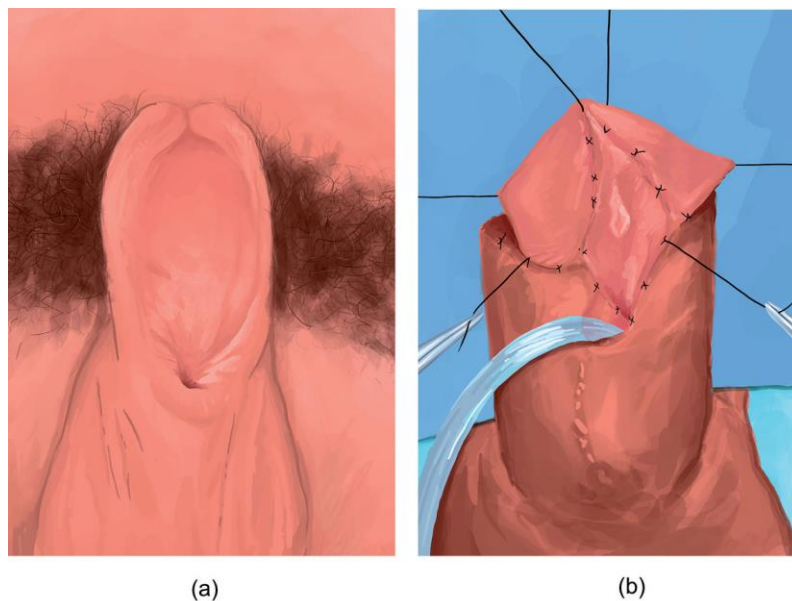
A study involving 58 patients who underwent a single-stage penile preputial flap urethroplasty for complex long-segment urethral strictures, excluding cases with lichen sclerosus, found that 87.93% of patients achieved a satisfactory outcome and the overall success rate was 81.03% (Mathur et al., 2014).

An observational study conducted at a single medical centre in China examined 155 children who performed transverse preputial island flap urethroplasty for the single-stage surgery of proximal hypospadias. The study found that there were 92 postoperative complications and 41 patients required reoperation. A total of 49 individuals presented with urinary fistula, 26 individuals had urethral stricture, 9 individuals had urethral diverticulum, and 8 individuals had urinary tract infections. The satisfaction rates for various aspects of the penis's cosmetic appearance among family members were as follows: 85.2% for the urinary meatus, 87.7% for the glans appearance, 92.3% for the foreskin appearance, and 89.0% for the overall penis shape (Cui et al., 2020).

### **Two-Stage Urethroplasty**

The original description of the two-stage process can be attributed to Turner-Warwick, with subsequent popularization by Bracka. Essentially, during the initial phase, Bracka employs a technique that involves the formation of a neo-urethral plate through the division of the glans and the release of chordee by cutting the existing urethral plate and removing any constricting chordee tissue from the corpora. Ideally, a free graft is harvested from the inner prepuce and afterwards affixed onto the denuded surface by a quilting technique. In all primary cases, the optimal choice for grafting is the utilization of surplus preputial skin. In circumstances when the preputial skin has already been sacrificed, the raw area can be covered using either surplus local penile skin or a postauricular graft. The graft is carefully strained and stitched to minimize displacement and accumulation inside the bedding, hence mitigating potential complications (Faure et al., 2016; Johal et al., 2006; Subramaniam et al., 2011).

As mentioned previously, the surgical approach involves various objectives such as orthoplasty, urethroplasty, glansplasty, meatoplasty, scrotoplasty, and skin coverage through circumcision or preputial reconstruction. These steps could be executed either in a single operation or in a staged manner. The approach should be customized for each specific case, primarily considering the extent of curvature and the quality of the urethral plate. Undoubtedly, most cases could be effectively treated in a single-step approach. In a small number of instances, penile curvature is severe enough to require simultaneous use of dorsal plication or ventral corporal grafting for correction. For certain specific situations, it might be necessary to divide the urethral plate to obtain a satisfactory straightening. In some cases, the urethral plate may be undeveloped and unsuitable for inclusion in the urethroplasty, even though it does not contribute to the curvature. A phased approach might be beneficial for all instances that require a urethral plate substitution (Haxhirexha KN et al., 2008; Keays & Dave, 2017; Steven et al., 2013).



**Figure 3. Two-stage distal urethra reconstruction as described by Bracka. (a–b) The first stage involves excising the damaged urethral mucosa and then performing marsupialization of the urethra, followed by implantation of an oral mucosal graft. The condition of the graft after 6 months, which is subsequently prepared for tubularization during the second stage (E. Martins et al., 2020)**

Recently, there have been technical advancements in the two-staged reconstructive procedure, specifically aimed at implementing a more assertive correction of chordee. Certain individuals may opt to elevate a dartos flap and reposition it towards the ventral side to provide a broader graft bed that is adequately supplied with blood vessels. This phenomenon facilitates improved graft integration and the occurrence of chordee relapse is infrequent. The repair was completed 6 months later using the Snodgrass modification of the standard Thiersch-Duplay technique. During the second stage of the procedure, the neo-urethral plate is tubularized, and the neourethra is covered by mobilizing the dorsal dartos flaps. A 1-cm strip of the plate is tubularized over an 8F or 10F silastic stent or Foley catheter. Additionally, two or preferably three layers, including skin closure, are performed to complete the process (Bracka, n.d.; Faure et al., 2016; Fawzy, 2023; Zheng et al., 2015).

The results of two-stage urethroplasty showed variable results. The majority of complications associated with two-stage urethroplasty often arise within the first 6-12 months following the second stage. However, in cases involving balanitis xerotica obliterans, the progressive retraction of the tube might develop for many years. In the context of repairing oral mucosa, the success rate of the recipient site appears to be much higher when the graft is obtained from the buccal site rather than the labial location. Like with any other methods, the primary complications of the staged repair procedure involve the development of fistulas, urethral strictures, and meatal stenosis (Haxhirexha KN et al., 2008).

A retrospective analysis was conducted on a cohort of patients diagnosed with proximal hypospadias who performed two-stage repair. The study included a total of 134 individuals and spanned 20 years. The findings revealed that the incidence of complications in this patient population reached a rate of 50% (McNamara et al., 2015).

A separate study with a duration of five years and involving 62 boys documented highly favourable outcomes in terms of both cosmetic and functional aspects following the completion of the

second stage. The complication incidence was found to be 18%, encompassing cases of partial glans dehiscence, residual moderate curvature, and meatal stenosis (Johal et al., 2006).

### **Which One Is Better for Hypospadias?**

Currently, there is no “one-size-fits” repair for hypospadias. Options for urethroplasty depend on the sites of the urethra for different types of strictures (Andrich & Mundy, 2008). For cases of proximal hypospadias, several studies still suggested that two-stage urethroplasty is better compared to single-stage and has comparable complications. A retrospectively studied 44 patients with glandular hypospadias with severe penile curvature reported that two-staged urethroplasty had significantly less occurrence of urethral stricture and better maximal urinary flow rate (Zhou et al., 2022). A separate study conducted at a single center evaluated 91 patients with proximal hypospadias who had undergone either one-stage or two-stage urethroplasty. The study found that two-stage urethroplasty, specifically using a tubularized urethral plate and transverse preputial island flap, could significantly decrease the occurrence of urethral fistula in patients with proximal hypospadias accompanied by severe chordee. Nevertheless, it could potentially increase the number of procedures required for children who actually do not require phased surgery (Zhu et al., 2021). A study found that using a two-stage repair with dermal graft clitoroplasty for severe hypospadias with moderate chordee resulted in significantly fewer postoperative problems and higher levels of parent satisfaction compared to using a single-stage Snodgrass urethroplasty repair (Hassan, 2014).

On the contrary, several studies reported that both had comparable results and complications (Badawy & Fahmy, 2013; Hoy et al., 2019). There are several elements that could come into play. While the use of one-stage urethroplasty presents an attractive option for reducing healthcare costs, hospital stay duration, anesthetic complications, and time to achieve desired outcomes, two-stage urethroplasty typically offers the advantage of a more favorable urethral bed and reduced formation of scar tissue surrounding the urethra. Theoretically, the two-stage repair procedure is expected to consistently yield superior cosmetic and functional outcomes. This is due to the interval between grafting and closure, which allows for the occurrence of all scarring and contractions surrounding the meatus prior to the second stage. Consequently, this approach enhances the likelihood of achieving a successful conclusion (Zheng et al., 2015). A possible explanation for the lower incidence of failure in the two-stage repair approach in a study could be attributed to a comparatively shorter duration of postoperative follow-up, the inclusion of a substantial proportion of bulbar strictures in both study groups, and the consistent implementation of a two-stage repair technique for all cases with hypospadias revisions and lichen sclerosus (Hoy et al., 2019). A surgeon’s preference or familiarity with the technique could also play some role, which might affect the results of the studies because one technique might be more prevalently used than the others.

### **CONCLUSION**

The fundamental principles of surgical procedures for hypospadias have remained consistent throughout the years. When it comes to urethroplasty, surgeons have the option to perform single- or two-stage procedures, each with its own set of advantages and disadvantages. However, it's important to note that the quality and number of studies consulted to determine the superiority of one over the other may vary. Currently, available studies present conflicting results, highlighting the absence of a universally superior technique. Ultimately, the decision to perform single- or two-stage urethroplasty depends on the individual patient's condition and the surgeon's preference, taking into consideration the breadth and depth of research findings.

### **REFERENCES**

---

- Agrawal, K., & Misra, A. (2013). Unfavourable results in hypospadias. *Indian Journal of Plastic Surgery*, 46(2), 419–427.
- Andrich, D. E., & Mundy, A. R. (2008). What is the Best Technique for Urethroplasty? In *European Urology* (Vol. 54, Issue 5, pp. 1031–1041). <https://doi.org/10.1016/j.eururo.2008.07.052>
- Appeadu-Mensah, W., Hesse, A. A. J., Glover-Addy, H., Osei-Nketiah, S., Etwire, V., & Sarpong, P. (2015). Complications of hypospadias surgery: Experience in a tertiary hospital of a developing country. *African Journal of Paediatric Surgery*, 12(4), 211–216. <https://doi.org/10.4103/0189-6725.172538>
- Aslam, R., Campbell, K., Wharton, S., & Bracka, A. (2013). Medium to long term results following single stage Snodgrass hypospadias repair. *Journal of Plastic, Reconstructive and Aesthetic Surgery*, 66(11), 1591–1595. <https://doi.org/10.1016/j.bjps.2013.06.041>
- Babu, R., & Chandrasekharam, V. V. S. (2021). Meta-analysis comparing the outcomes of single stage (foreskin pedicled tube) versus two stage (foreskin free graft & foreskin pedicled flap) repair for proximal hypospadias in the last decade. In *Journal of Pediatric Urology* (Vol. 17, Issue 5, pp. 681–689). Elsevier Ltd. <https://doi.org/10.1016/j.jpuro.2021.05.014>
- Badawy, H., & Fahmy, A. (2013). Single- vs. Multi-stage repair of proximal hypospadias: The dilemma continues. In *Arab Journal of Urology* (Vol. 11, Issue 2, pp. 174–181). <https://doi.org/10.1016/j.aju.2013.03.009>
- Baskin, L. (2017). What is hypospadias? In *Clinical Pediatrics* (Vol. 56, Issue 5, pp. 409–418). SAGE Publications Inc. <https://doi.org/10.1177/0009922816684613>
- Bergman, J. E. H., Loane, M., Vrijheid, M., Pierini, A., Nijman, R. J. M., Addor, M. C., Barisic, I., Béres, J., Braz, P., Budd, J., Delaney, V., Gatt, M., Khoshnood, B., Klungsoyr, K., Martos, C., Mullaney, C., Nelen, V., Neville, A. J., O'Mahony, M., ... de Walle, H. E. K. (2015). Epidemiology of hypospadias in Europe: a registry-based study. *World Journal of Urology*, 33(12), 2159–2167. <https://doi.org/10.1007/s00345-015-1507-6>
- Bhat, A., Sabharwal, K., Bhat, M., Saran, R., Singla, M., & Kumar, V. (2014). Outcome of tubularized incised plate urethroplasty with spongioplasty alone as additional tissue cover: A prospective study. *Indian Journal of Urology*, 30(4), 392–397. <https://doi.org/10.4103/0970-1591.134234>
- Bouty, A., Ayers, K. L., Pask, A., Heloury, Y., & Sinclair, A. H. (2015). The genetic and environmental factors underlying hypospadias. In *Sexual Development* (Vol. 9, Issue 5, pp. 239–259). S. Karger AG. <https://doi.org/10.1159/000441988>
- Bracka, A. (n.d.). The role of two-stage repair in modern hypospadiology. In *Indian Journal of Urology* (Vol. 210).
- Bush, N. C., Villanueva, C., & Snodgrass, W. (2015). Glans size is an independent risk factor for urethroplasty complications after hypospadias repair. *Journal of Pediatric Urology*, 11(6), 355.e1-355.e5. <https://doi.org/10.1016/j.jpuro.2015.05.029>
- Chandrasekharam, V. V. S. (2013). Single-stage repair of hypospadias using longitudinal dorsal island flap: Single-surgeon experience with 102 cases. *Indian Journal of Urology*, 29(1), 48–52. <https://doi.org/10.4103/0970-1591.109984>
- Chen, M. J., Karaviti, L. P., Roth, D. R., & Schlomer, B. J. (2018). Birth prevalence of hypospadias and hypospadias risk factors in newborn males in the United States from 1997 to 2012. *Journal of Pediatric Urology*, 14(5), 425.e1-425.e7. <https://doi.org/10.1016/j.jpuro.2018.08.024>
- Cui, X., He, Y., Huang, W., Chen, L., Wang, Y., & Zhou, C. (2020). Clinical efficacy of transverse preputial island flap urethroplasty for single-stage correction of proximal hypospadias: a
-

- single-centre experience in Chinese patients. *BMC Urology*, 20(1).  
<https://doi.org/10.1186/s12894-020-00686-3>
- Dason, S., Wong, N., & Braga, L. H. (2014). The contemporary role of 1 vs. 2-stage repair for proximal hypospadias. *Translational Andrology and Urology*, 3(4), 347–358.  
<https://doi.org/10.3978/j.issn.2223-4683.2014.11.04>
- Duarsa, G. W. K., Tirtayasa, P. M. W., Daryanto, B., Nurhadi, P., Renaldo, J., Tarmono, Utomo, T., Yuri, P., Siregar, S., Wahyudi, I., Situmorang, G. R., Ansharullah Palinrungi, M. A., Hutasoit, Y. I., Hutahaean, A. Y. A., Zulfiqar, Y., Sigumonrong, Y. H., Mirza, H., Rodjani, A., & Kloping, Y. P. (2020). Risk factors for urethrocutaneous fistula following hypospadias repair surgery in Indonesia. *Journal of Pediatric Urology*, 16(3), 317.e1-317.e6.  
<https://doi.org/10.1016/j.jpuro.2020.04.011>
- E. Martins, F., Simoes de Oliveira, P., & M. Martins, N. (2020). Historical Perspective and Innovations in Penile Urethroplasty. In *Lower Urinary Tract Dysfunction - From Evidence to Clinical Practice*. IntechOpen. <https://doi.org/10.5772/intechopen.85908>
- Emir, H., Jayanthi, V. R., Nitahara, K., Danismend, N., & Koff, S. A. (2000). Modification of The Koyanagi Technique for The Single Stage Repair of Proximal Hypospadias. *The Journal of Urology*, 164, 973–976.
- Epelboym, Y., Estrada, C., & Estroff, J. (2017). Ultrasound diagnosis of fetal hypospadias: Accuracy and outcomes. *Journal of Pediatric Urology*, 13(5), 484.e1-484.e4.  
<https://doi.org/10.1016/j.jpuro.2017.02.022>
- Faure, A., Bouty, A., Nyo, Y. L., O'Brien, M., & Heloury, Y. (2016). Two-stage graft urethroplasty for proximal and complicated hypospadias in children: A retrospective study. *Journal of Pediatric Urology*, 12(5), 286.e1-286.e7. <https://doi.org/10.1016/j.jpuro.2016.02.014>
- Fawzy, A. (2023). Single-Stage Vs Two-Stage Urethroplasty For Hypospadias. *International Journal of Health and Clinical Research*, 6(1), 9–14. [www.ijhcr.com](http://www.ijhcr.com)9
- Fernández, N., Pérez, J., Monterrey, P., Poletta, F. A., Bägli, D. J., Lorenzo, A. J., & Zarante, I. (2017). ECLAMC study: Prevalence patterns of hypospadias in South America: Multi-national analysis over a 24-year period. *International Braz J Urol*, 43(2), 325–334.  
<https://doi.org/10.1590/S1677-5538.IBJU.2016.0002>
- Gite, V. A., Nikose, J. V., Bote, S. M., & Patil, S. R. (n.d.). *Anterior Urethral Advancement as a Single-Stage Technique for Repair of Anterior Hypospadias: Our Experience RECONSTRUCTIVE SURGERY*.
- Goel, H. K., Tirthraj, C. M., Kabra, S., Gahlawat, S., Sharma, U., & Sood, R. (2021). Factors affecting outcome of adult hypospadias single stage repair: A prospective observational study. *Turkish Journal of Urology*, 47(5), 420–426. <https://doi.org/10.5152/tud.2021.21163>
- González, R., Lingnau, A., & Ludwikowski, B. M. (2018). Results of onlay preputial flap urethroplasty for the single-stage repair of mid- and proximal hypospadias. *Frontiers in Pediatrics*, 6. <https://doi.org/10.3389/fped.2018.00019>
- Hadidi, A. T. (2009). Lateral-based flap: a single stage urethral reconstruction for proximal hypospadias. *Journal of Pediatric Surgery*, 44(4), 797–801.  
<https://doi.org/10.1016/j.jpedsurg.2008.08.012>
- Hadidi, A. T. (2022). *Hypospadias Surgery An Illustrated Textbook* (Second Edition). Springer. <https://doi.org/https://doi.org/10.1007/978-3-030-94248-9>
- Hassan, M. E. (2014). Two-stage versus single-stage repair for severe hypospadias with moderate chordee. *Annals of Pediatric Surgery*, 10(4), 125–129.  
<https://doi.org/10.1097/01.XPS.0000452989.89735.fa>
-

- Haxhirexha KN, Castagnetti, M., Rigamonti, W., & Manzoni, G. (2008). Two-stage repair in hypospadias. *Indian Journal of Urology*, 24(2), 226–232.
- Hayashi, Y., Kojima, Y., Mizuno, K., Nakane, A., Kurokawa, S., Maruyama, T., & Kohri, K. (2007). Neo-modified Koyanagi technique for the single-stage repair of proximal hypospadias. *Journal of Pediatric Urology*, 3(3), 239–242. <https://doi.org/10.1016/j.jpuro.2006.06.007>
- Hoy, N. Y., Chapman, D. W., & Rourke, K. F. (2019). Better defining the optimal management of penile urethral strictures: A retrospective comparison of single-stage vs. Two-stage urethroplasty. *Canadian Urological Association Journal*, 13(12), 414–418. <https://doi.org/10.5489/cuaj.5895>
- Johal, N. S., Nitkunan, T., O'Malley, K., & Cuckow, P. M. (2006). The Two-Stage Repair for Severe Primary Hypospadias. *European Urology*, 50(2), 366–371. <https://doi.org/10.1016/j.eururo.2006.01.002>
- Kajbafzadeh, A. M., Arshadi, H., Payabvash, S., Salmasi, A. H., Najjaran-Tousi, V., & Sahebpor, A. R. A. (2007). Proximal Hypospadias With Severe Chordee: Single Stage Repair Using Corporeal Tunica Vaginalis Free Graft. *Journal of Urology*, 178(3), 1036–1042. <https://doi.org/10.1016/j.juro.2007.05.062>
- Keays, M. A., & Dave, S. (2017). Current hypospadias management: Diagnosis, surgical management, and long-term patient-centred outcomes. In *Canadian Urological Association Journal* (Vol. 11, Issues 1–2, pp. S48–S53). Canadian Urological Association. <https://doi.org/10.5489/cuaj.4386>
- Khan, M., Majeed, A., Hayat, W., Ullah, H., Naz, S., Shah, S. A., Tahmeed, T., Yousaf, K., & Tahir, M. (2014). Hypospadias Repair: A Single Centre Experience. *Plastic Surgery International*, 2014, 1–7. <https://doi.org/10.1155/2014/453039>
- Kraft, K. H., Shukla, A. R., & Canning, D. A. (2010). Hypospadias. In *Urologic Clinics of North America* (Vol. 37, Issue 2, pp. 167–181). <https://doi.org/10.1016/j.ucl.2010.03.003>
- Leunbach, T. L., O'Toole, S., Springer, A., Williamson, P. R., & Ahmed, S. F. (2020). A Systematic Review of Core Outcomes for Hypospadias Surgery. *Sexual Development*, 13(4), 165–170. <https://doi.org/10.1159/000504973>
- Manzoni, G., Bracka, A., Palminteri, E., & Marrocco, G. (2004). Hypospadias surgery: when, what and by whom? *BJU International*, 94(8), 1188–1195. <https://doi.org/10.1111/j.1464-410X.2004.05128.x>
- Mathur, R. K., Nagar, M., Mathur, R., Khan, F., Deshmukh, C., & Guru, N. (2014). Single-stage preputial skin flap urethroplasty for long-segment urethral strictures: Evaluation and determinants of success. *BJU International*, 113(1), 120–126. <https://doi.org/10.1111/bju.12361>
- McNamara, E. R., Schaeffer, A. J., Logvinenko, T., Seager, C., Rosoklija, I., Nelson, C. P., Retik, A. B., Diamond, D. A., & Cendron, M. (2015). Management of proximal hypospadias with 2-stage repair: 20-year experience. *Journal of Urology*, 194(4), 1080–1085. <https://doi.org/10.1016/j.juro.2015.04.105>
- Nordenvall, A. S., Frisén, L., Nordenström, A., Lichtenstein, P., & Nordenskjöld, A. (2014). Population based nationwide study of hypospadias in Sweden, 1973 to 2009: Incidence and risk factors. *Journal of Urology*, 191(3), 783–789. <https://doi.org/10.1016/j.juro.2013.09.058>
- Ru, W., Tang, D., Wu, D., Tao, C., Chen, G., Wei, J., Tian, H., & Shu, Q. (2021). Identification of risk factors associated with numerous reoperations following primary hypospadias repair. *Journal of Pediatric Urology*, 17(1), 61.e1–61.e5. <https://doi.org/10.1016/j.jpuro.2020.11.010>
-

- Schönbucher, V. B., Weber, D. M., & Landolt, M. A. (2008). Psychosocial adjustment, health-related quality of life, and psychosexual development of boys with hypospadias: A systematic review. In *Journal of Pediatric Psychology* (Vol. 33, Issue 5, pp. 520–535). <https://doi.org/10.1093/jpepsy/jsm098>
- Schwentner, C., Gozzi, C., Lunacek, A., Rehder, P., Bartsch, G., Oswald, J., & Radmayr, C. (2006). Interim Outcome of the Single Stage Dorsal Inlay Skin Graft for Complex Hypospadias Reoperations. *Journal of Urology*, 175(5), 1872–1877. [https://doi.org/10.1016/S0022-5347\(05\)01016-5](https://doi.org/10.1016/S0022-5347(05)01016-5)
- Sheng, X., Xu, D., Wu, Y., Yu, Y., Chen, J., & Qi, J. (2018). The risk factors of Urethrocutaneous fistula after hypospadias surgery in the youth population. *BMC Urology*, 18(1). <https://doi.org/10.1186/s12894-018-0366-z>
- Singal, A. K., Dubey, M., & Jain, V. (2016). Transverse preputial onlay island flap urethroplasty for single-stage correction of proximal hypospadias. *World Journal of Urology*, 34(7), 1019–1024. <https://doi.org/10.1007/s00345-015-1686-1>
- Snodgrass, W. T. (2011). Hypospadias. In *Pediatric Urology* (pp. 177–190). Humana Press. [https://doi.org/10.1007/978-1-60327-420-3\\_9](https://doi.org/10.1007/978-1-60327-420-3_9)
- Springer, A., Tekgul, S., & Subramaniam, R. (2017). An Update of Current Practice in Hypospadias Surgery. In *European Urology, Supplements* (Vol. 16, Issue 1, pp. 8–15). Elsevier B.V. <https://doi.org/10.1016/j.eursup.2016.09.006>
- Springer, A., van den Heijkant, M., & Baumann, S. (2016). Worldwide prevalence of hypospadias. *Journal of Pediatric Urology*, 12(3), 152.e1-152.e7. <https://doi.org/10.1016/j.jpuro.2015.12.002>
- Stein, R. (2012). Hypospadias. *European Urology, Supplements*, 11(2), 33–45. <https://doi.org/10.1016/j.eursup.2012.01.002>
- Steven, L., Cherian, A., Yankovic, F., Mathur, A., Kulkarni, M., & Cuckow, P. (2013). Current practice in paediatric hypospadias surgery; A specialist survey. *Journal of Pediatric Urology*, 9(6 PART B), 1126–1130. <https://doi.org/10.1016/j.jpuro.2013.04.008>
- Subramaniam, R., Spinoit, A. F., & Hoebeke, P. (2011). Hypospadias repair: An overview of the actual techniques. In *Seminars in Plastic Surgery* (Vol. 25, Issue 3, pp. 206–212). <https://doi.org/10.1055/s-0031-1281490>
- Tiryaki, T. (2010). Combination of tubularized Island flap and ventral skin flap techniques in single-stage correction of severe proximal hypospadias. *Urologia Internationalis*, 84(3), 269–274. <https://doi.org/10.1159/000288227>
- van der Horst, H. J. R., & de Wall, L. L. (2017). Hypospadias, all there is to know. In *European Journal of Pediatrics* (Vol. 176, Issue 4, pp. 435–441). Springer Verlag. <https://doi.org/10.1007/s00431-017-2864-5>
- Van Rooij, I. A. L. M., Van Der Zanden, L. F. M., Brouwers, M. M., Knoers, N. V. A. M., Feitz, W. F. J., & Roeleveld, N. (2013). Risk factors for different phenotypes of hypospadias: Results from a dutch case-control study. In *BJU International* (Vol. 112, Issue 1, pp. 121–128). <https://doi.org/10.1111/j.1464-410X.2012.11745.x>
- Winston, J. J., Meyer, R. E., & Emch, M. E. (2014). Geographic analysis of individual and environmental risk factors for hypospadias births. *Birth Defects Research Part A - Clinical and Molecular Teratology*, 100(11), 887–894. <https://doi.org/10.1002/bdra.23306>
- Xu, L. F., Liang, C. Z., Lipianskaya, J., Chen, X. G., Fan, S., Zhang, L., Zhou, J., Tai, S., & Jiang, C. Q. (2014). Risk factors for hypospadias in China. *Asian Journal of Andrology*, 16(5), 778. <https://doi.org/10.4103/1008>
-

- Zheng, D. C., Yao, H. J., Cai, Z. K., Da, J., Chen, Q., Chen, Y. B., Zhang, K., Xu, M. X., Lu, M. J., & Wang, Z. (2015). Two-stage urethroplasty is a better choice for proximal hypospadias with severe chordee after urethral plate transection: A single-center experience. *Asian Journal of Andrology*, *17*(1), 94–97. <https://doi.org/10.4103/1008-682X.137688>
- Zhou, G., Xu, W., Yin, J., Sun, J., Yang, Z., & Li, S. (2022). Single-stage versus staged interposition urethroplasty for glandular hypospadias with severe penile curvature: 15-year experience. *World Journal of Urology*, *40*(1), 155–160. <https://doi.org/10.1007/s00345-021-03829-9>
- Zhu, X., Huang, L., Wang, J., Zhu, H., Chen, C., Wang, L., Deng, Y., Ma, G., Guo, Y., & Ge, Z. (2021). Comparative study of one-stage and the novel two-stage urethroplasty using the transected urethral plate and transverse preputial island flap (TPIF) for severe hypospadias: a single-center experience. In *Translational Pediatrics* (Vol. 10, Issue 4, pp. 998–1007). AME Publishing Company. <https://doi.org/10.21037/TP-20-392>



© 2023 by the authors. It was submitted for possible open-access publication under the terms and conditions of the Creative Commons Attribution (CC BY SA) license (<https://creativecommons.org/licenses/by-sa/4.0/>).